

---

## How I Do It

---

# Scalp as Split Thickness Skin Graft Donor Site for Congenital Atresia Repair

---

Hernan Goldsztein, MD; Stuart Ort, MD; Joseph B. Roberson, MD Jr; John Reinisch, MD

**Objective:** Describe the use of the scalp as a donor site for split thickness skin grafts in otologic surgery.

**Materials and Methods:** Review of the literature with detailed description of surgical technique and authors' experience.

**Results:** One hundred and forty-four scalp split thickness skin grafts were obtained between 2007 and 2011. No significant complications were observed with optimal cosmetic results.

**Conclusions:** The scalp is a viable option as a split thickness skin graft donor site for otologic and other head and neck surgery. Advantages include improved cosmetic results at the donor site, quick healing with low complication rates, and easy accessibility in the operative field.

**Key Words:** External ear, congenital anomalies, nonmicrovascular reconstruction, grafts, flaps.

**Level of Evidence:** NA.

*Laryngoscope*, 000:000-000, 2012

## INTRODUCTION

Congenital atresia repair requires creation of an external auditory canal. Split thickness skin grafts (STSG) are used to line the new bony conduit. Traditional donor sites are the limbs or buttocks, however these areas present a series of major and minor disadvantages. Major disadvantages include a slow healing process and a visible unpleasant scar. Minor disadvantages are the need for a separate sterile site at the time of surgery, as well as donor site pain for daily activities, as these areas tend to have contact with cloths or the patient's own body during motion.

Crawford first reported the scalp as a donor site in 1964.<sup>1</sup> Since then, multiple plastic surgeons treating burn victims have described their experience.<sup>2,3</sup> Stated advantages for the scalp as a donor site include reliability, low rate of complications, fast healing, ability to

quickly reharvest, and inconspicuous scar both by better healing and mascaared by the growing hair. We started to use this technique for congenital atresia, and subsequently for acquired atresia with excellent results. To the best of our knowledge, this is the first report of the use of the scalp as a donor site for otologic surgery. We describe our technique, as well as a review of outcomes for 144 grafts obtained between 2007 and 2011.

## MATERIALS AND METHODS

The present study obtained was reviewed and received a waiver as minimal risk by the Western Institutional Review Board. All patients were evaluated and treated at a private subspecialty clinic.

### Consent

As part of the general consent, we describe the use of STSG. We discuss general risks, benefits, and alternative donor sites, as well as possible complications including blood loss, alopecia, and hypertrophic scar.

### Surgical Technique

The setup resembles a standard otology/atresia case, with the exception that a greater area is shaved in the temporoparietal/occipital regions. Most of our patients are pediatric, but we still tend to locate the donor site closer to the occipital region in order to avoid a visible scar in future balding areas.

The hair shaft is trimmed to a length of 2-mm to allow easier subsequent hair removal (Fig. 1a). The donor site is prepped and draped in the usual sterile fashion and hydrodissection is carried out with diluted local anesthetic (bupivacaine 0.06% epinephrine 1:800,000) infusing abundantly under the galea aponeurosis (Fig. 1b). Extra local anesthetic is infiltrated

---

From the California Ear Institute (H.G., S.O., J.B.R.), East Palo Alto, California, U.S.A.; Department of Surgery (J.R.), Cedars-Sinai Medical Center, Los Angeles, California, U.S.A.

Editor's Note: This Manuscript was accepted for publication June 7, 2012.

Financial Disclosure: Hernan Goldsztein (Consulting): Acclarent Menlo Park, CA; Stuart Ort (Consulting): Autonomic Technologies Inc, Redwood City, CA; Joseph B. Roberson (Consulting Advisory Relationships, Equity Positions, or Ownership Interests): Acclarent Menlo Park, CA; Autonomic Technologies Inc Redwood City, CA; Vigilo Networks Campbell, CA; Lumenis Santa Clara, CA; Kurz Dusslingen Germany; The Doctor's Company, Napa, CA; Inspire Maple Grove, MN; Neupace-Mountain View, CA; and Global Hearing E Palo Alto, CA; John Reinisch: None.

Send correspondence to Joseph B. Roberson, California Ear Institute, 1900 University Ave., Suite 101, East Palo Alto, CA 94303. E-mail: jbr@calear.com

DOI: 10.1002/lary.23552

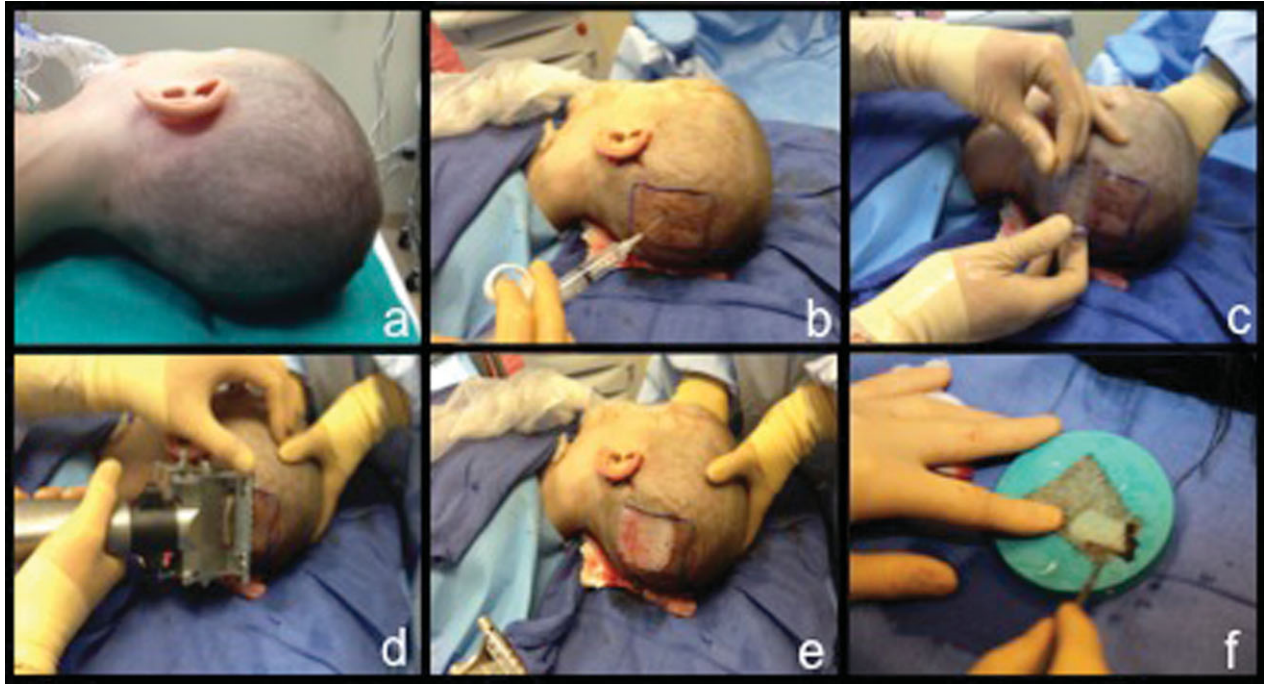


Fig. 1. (a) Shows the preparation of the surgical site. The hair shaft is trimmed to a length of 2 mm to allow easier subsequent hair removal. (b) After sterile preparation and draping the donor site is infiltrated abundantly under the galea aponeurosis with diluted anesthetic with epinephrine. (c) A small measuring cup is used to level and distribute the fluid. (d) A dermatome is used to obtain the split thickness graft. The thickness of the graft is set between 0.2 and 0.25 mm to avoid injury to the hair follicle. (e) Once the graft has been harvested, the donor site can be covered with moist gauze. (f) On a back table, the remaining hair shafts on the STSG are removed with the use of a 15 blade or a blunt object. Care must be taken at all times to keep the graft moist and to remove all hairs.

around the lesser and greater occipital nerves to further anesthetize the donor site. A small measuring cup is used to level and distribute the fluid (Fig. 1c). A cordless dermatome (Acculan 3Ti, Aesculap Inc, Center Valley, PA) is used to obtain the split thickness graft. The thickness of the graft is set between 0.2 and 0.25 mm to avoid injury to the hair follicle. The pressure exerted by the operator should be even throughout the harvesting procedure (Fig. 1d).

Once the graft has been harvested, the donor site can be covered with moist gauze. We dress the donor site with antibiotic ointment and nonadherent gauze with or without Xeroform™ (Tyco Healthcare/Kendall, Mansfield MA). On a back table, the remaining hair shafts on the STSG are removed with the use of a 15 blade or a blunt object (Fig. 1f). Jeweler's forceps are used to remove the last hairs usually under the microscope. Care must be taken at all times to keep the graft

moist and to remove all hairs. The undersurface of the graft must be free of hair to avoid a foreign body reaction.

#### Donor Site Care

Patients are routinely followed at 1 and 3 weeks post-op. The dressing was removed POD#6-7 in compliant patients. Otherwise we allow the nonadherent gauze to fall off on its own. Showering is allowed after the first follow-up.

#### RESULTS

One hundred and forty-four scalp STSGs were obtained since adoption of this technique in 2007. Complications included one local infection treated with topical and oral antibiotics, and one mild alopecia noted.

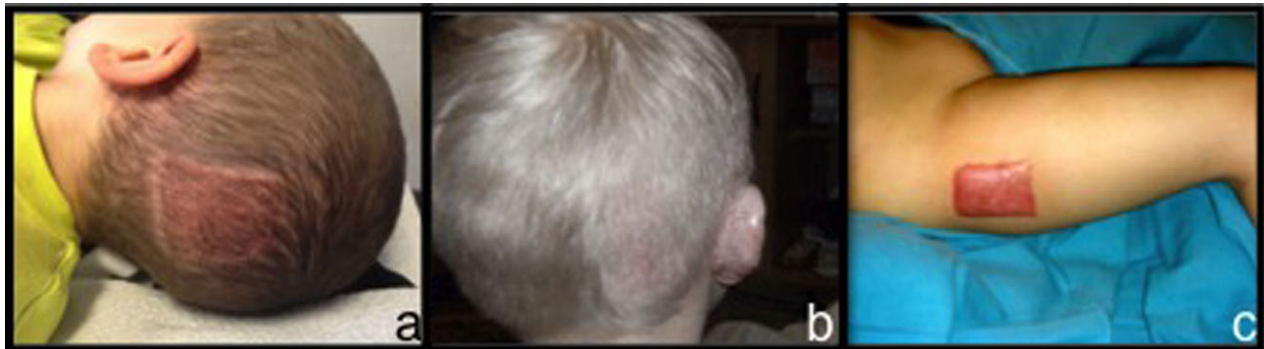

Fig. 2. (a) Shows the donor site 3 weeks post op. Notice hair growth already present. (b) Postoperative results 12 months after surgery (on a different patient). (c) Hypertrophic scarring of the thigh as a STSG donor site 12 months post-op.

Remarkably, no hypertrophic or keloid scarring was observed in spite of having a significant proportion of patients of Asian descent (22%).

Reepithelialization and hair growth was consistently observed 3 weeks after the operation at the donor site (Figure 2a). Meatal stenosis requiring revision was seen in 6.9% (10 patients). This is comparable to the senior authors' previous work where STSG were obtained from the thigh (7.1%).<sup>4</sup> There were no graft failures in this series and no hair growth in the skin graft.

## DISCUSSION

The scalp has been well documented as a reliable donor site for split thickness skin grafts. The stated advantages include equal quality to other sites with quicker healing, improved patient comfort and better cosmetic results.<sup>2,3</sup>

In a prospective study in pediatric patients by Martinot et al.,<sup>2</sup> the scalp was found to provide as good as a graft as more traditional locations, with less donor site morbidity in 1 year follow-up. There was no associated alopecia. The authors found the scalp to be technically more demanding than the thigh.

In a retrospective review of 945 scalp STSG by Mimoun, et al.,<sup>3</sup> the mean healing time was 6.8 days for single harvest compared to 14 days for other donor sites. They also found reharvesting possible up to six times. There was better patient comfort due to rapid healing with consequent less need for dressing changes. Cosmetic results were superior due to lower rates of scarring and the hair growing back very quickly concealed any postoperative pigmentation changes.

Plausible explanations for these advantages include rich vascularization of the scalp and a high hair density, providing a greater source of basal cells for reepithelialization. It is not clear why scarring is less common.

Potential disadvantages include alopecia and greater blood loss. In Brou et al., review of 194 pediatric patients they cautioned, "The scalp cannot be used as a donor without impunity".<sup>5</sup> They found a 32% incidence of alopecia in burn victims after harvesting STSG from the scalp. Looking closer at the data they found that patients with scalp burns had a 61% incidence of alope-

cia while the ones without concomitant burns had a 13% rate. Furthermore in this subgroup alopecia was associated with frequent reharvesting. In concordance to other authors<sup>2,3</sup> we have not found alopecia to be a common side effect. This is explained by the fact that the bulb of the hair follicle is located between 1–1.8-mm from the skin surface.<sup>6</sup> The dermatome is set to a depth of 0.2–0.25-mm preserving the reparative capacity of the follicle.

Additionally, our patients are not burn victims and the few reharvests are performed months after the original surgery.

Blood loss has been stated to be up to four times greater in the scalp after harvesting a STSG compared to other donor sites.<sup>7</sup> We have not quantified the blood loss, however, we did not find it to be significant after infiltration with a diluted adrenalized anesthetic solution as Mimoun's group.<sup>3</sup> We operate on young children and neither the epinephrine or blood loss has translated into significant hemodynamic shifts.

## CONCLUSION

The scalp is a valuable split thickness skin graft donor site. Advantages include quick healing and improved cosmetic results, with low complication rates. It is particularly attractive for otologic and other head and neck surgeries as it is usually in close proximity to the surgical field.

## BIBLIOGRAPHY

1. Crawford B S. An unusual skin donor site. *Br J Plast Surg* 1964;17:311.
2. Martinot V, Mitchell V, Fevrier P, Duhamel A, Pellerin P. Comparative study of split thickness grafts taken from the scalp and thigh in children. *Burns* 1994;20:146.
3. Mimoun M, Chaouat M, Picovski D, Serroussi D, Smarrito S. The scalp is an advantageous donor site for thin-skin grafts: A report on 945 harvested samples. *Plast and Reconstr Surg*, 2006;118:369–373.
4. Roberson J, Reinisch J, Colen T, Lewin S. Atresia repair before microtia reconstruction: comparison of early with standard surgical timing. *Otol Neurotol* 30:771–776.
5. Brou J, Vu T, McCauley RL, et al. The scalp as a donor site: revisited. *J Trauma* 1990;30:579–81.
6. Jimenez F, Izeta A, Poblet E. Morphometric analysis of the human scalp hair follicle: practical implications for the hair transplant surgeon and hair regeneration studies. *Dermatol Surg* 2010;37:58–64.
7. Mariani, U. Split skin grafts from the scalp. *Rev Hosp Clin Fac Med Sao Paulo* 1988;43:267